



**CORSO DI AGGIORNAMENTO E FORMAZIONE COLPOSCOPISTI DEL
2° LIVELLO SCREENING PER IL CERVICOCARCINOMA CON L'AVVIO
DEL NUOVO PROGRAMMA REGIONALE E UTILIZZO DEL TEST HPV
COME TEST PRIMARIO**

07/04/2014

LINEE GUIDA AMERICANE

Giovanni Maina

IV Struttura Complessa di Ostetricia e Ginecologia

“STANDARD AND QUALITY IN COLPOSCOPY”

D. Luesley

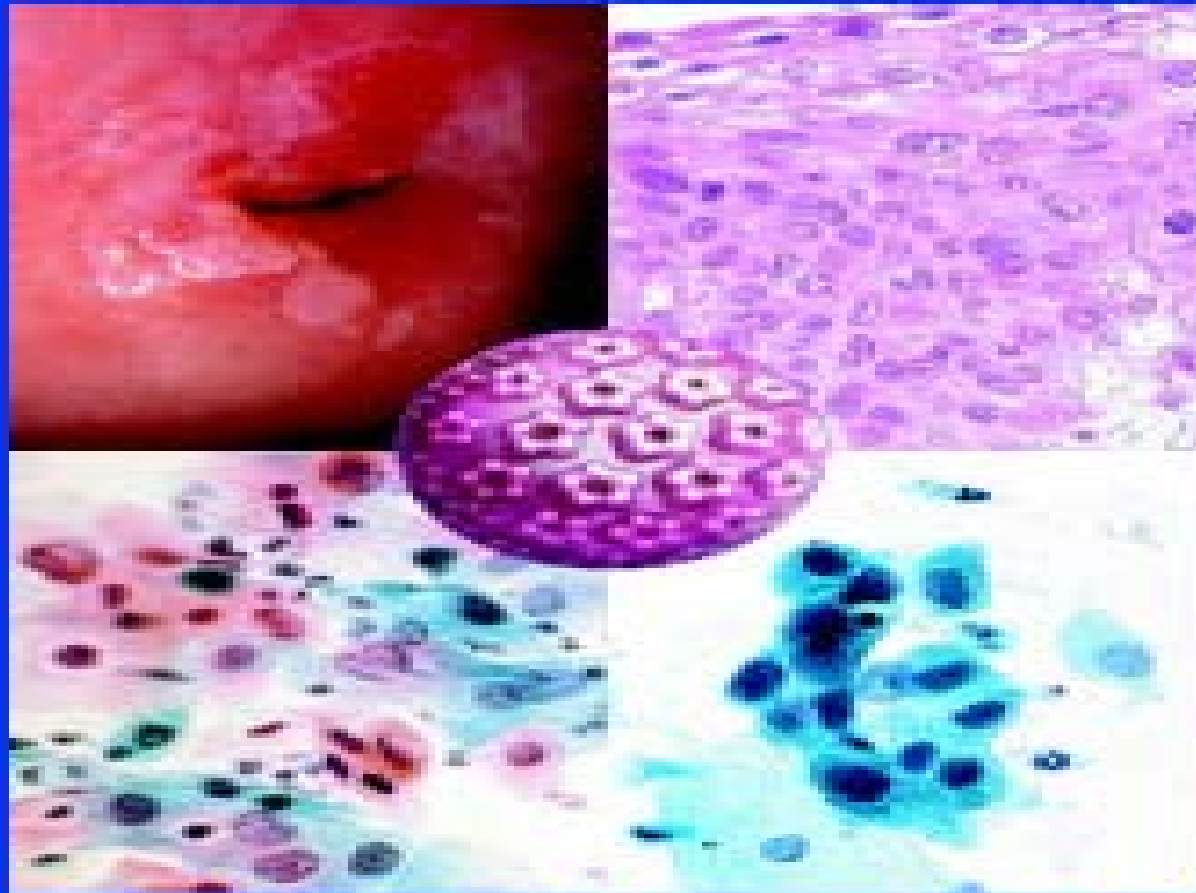
NHSCSP–Publication n° 2 January 1996

**“COLPOSCOPY AND PROGRAMME
MANAGEMENT”**

NHSCSP- Publication n.20 April 2004

NHSCSP- Publication n.20 May 2010

European guidelines for quality assurance in cervical cancer screening, issue 2, 2008



European guidelines for quality assurance
in cervical cancer screening, Second Edition



European Commission

2008

REVIEW

Annals of Oncology 21:448-458,2010

**EUROPEAN GUIDELINES FOR QUALITY ASSURANCE IN
CERVICAL CANCER SCREENING. SECOND EDITION-
SUMMARY DOCUMENT**

M. Arbyn, A. Anttila, J. Jordan, G. Ronco, U. Schenck, N. Segnan, H. Wiener, A. Herbert & L. von Karsa.

**GESTIONE DELLA PAZIENTE CON PAP TEST ANORMALE
LINEE GUIDA DELLA SOCIETA' ITALIANA DI
COLPOSCOPIA E PATOLOGIA CERVICO VAGINALE
EDIZIONE 2006**

**MANUALE DEL II LIVELLO
RACCOMANDAZIONI PER LA QUALITA' NELLA DIAGNOSI,
TERAPIA E FOLLOW UP DELLE LESIONI CERVICALI,
NELL'AMBITO DEI PROGRAMMI DI SCREENING
GISCI 2009**

COLPOSCOPIC MANAGEMENT OF ABNORMAL CERVICAL CYTOLOGY AND HISTOLOGY

SOGC JOINT CLINICAL PRACTICE GUIDELINE December 2012

This clinical practice guideline has been prepared by the Executive Council of the Society of Canadian Colposcopists and approved by the Society of Obstetricians and Gynecologists of Canada/Society of Gynecologic Oncology of Canada/Society of Canadian Colposcopists Policy and Practice Guidelines Committee, the Executive and Council of the Society of Obstetricians and Gynecologists of Canada

SYDNEY CANCER CENTRE
SYDNEY GYNAECOLOGICAL ONCOLOGY GROUP

CERVICAL DYSPLASIA

http://www.sswahs.nsw.gov.au/services/sgog/Dysplasia_Guide.html

American Cancer Society, American Society for Colposcopy and Cervical Pathology, and American Society for Clinical Pathology Screening Guidelines for the Prevention and Early Detection of Cervical Cancer

Debbie Saslow, PhD,¹ Diane Solomon, MD,² Herschel W. Lawson, MD,³ Maureen Killackey, MD,⁴ Shalini L. Kulasingam, PhD,⁵ Joanna Cain, MD,⁶ Francisco A. R. Garcia, MD, MPH,⁷ Ann T. Moriarty, MD,⁸ Alan G. Waxman, MD, MPH,⁹ David C. Wilbur, MD,¹⁰ Nicolas Wentzensen, MD, PhD, MS,¹¹ Levi S. Downs, Jr, MD,¹² Mark Spitzer, MD,¹³ Anna-Barbara Moscicki, MD,¹⁴ Eduardo L. Franco, DrPH,¹⁵ Mark H. Stoler, MD,¹⁶ Mark Schiffman, MD,¹⁷ Philip E. Castle, PhD, MPH,^{18} and Evan R. Myers, MD, MPH^{19*}*

¹Director, Breast and Gynecologic Cancer, Cancer Control Science Department, American Cancer Society, Atlanta, GA, on behalf of the Steering Committee, Data Group, and Writing Committee; ²Senior Investigator, Division of Cancer Prevention, National Cancer Institute, National Institutes of Health, Rockville, MD, on behalf of the Steering Committee; ³Adjunct Associate Professor, Department of Gynecology and Obstetrics, Emory University School of Medicine, Atlanta, GA, on behalf of the Data Group; ⁴Deputy Physician in Chief, Medical Director, Memorial Sloan-Kettering Cancer Center Regional Network, Department of Surgery, Gynecology Service, Memorial Sloan-Kettering Cancer Center,

Summary of Recommendations

Population	Recommended Screening Method [†]	Management of Screen Results	Comments
Aged <21 y	No screening		HPV testing should not be used for screening or management of ASC-US in this age group
Aged 21-29 y	Cytology alone every 3 y	HPV-positive ASC-US [†] or cytology of LSIL or more severe: Refer to ASCCP guidelines ² Cytology negative or HPV-negative ASC-US [†] : Rescreen with cytology in 3 y	HPV testing should not be used for screening in this age group
Aged 30-65 y	HPV and cytology “cotesting” every 5 y (preferred) Cytology alone every 3 y (acceptable)	HPV-positive ASC-US or cytology of LSIL or more severe: Refer to ASCCP guidelines ² HPV positive, cytology negative: Option 1: 12-mo follow-up with cotesting Option 2: Test for HPV16 or HPV16/18 genotypes • If HPV16 or HPV16/18 positive: refer to colposcopy • If HPV16 or HPV16/18 negative: 12-mo follow-up with cotesting Cotest negative or HPV-negative ASC-US: Rescreen with cotesting in 5 y HPV-positive ASC-US [†] or cytology of LSIL or more severe: Refer to ASCCP guidelines ² Cytology negative or HPV-negative ASC-US [†] : Rescreen with cytology in 3 y	Screening by HPV testing alone is not recommended for most clinical settings [†]
Aged >65 y	No screening following adequate negative prior screening		Women with a history of CIN2 or a more severe diagnosis should continue routine screening for at least 20 y

Summary of Recommendations

Population	Recommended Screening Method[†]	Management of Screen Results	Comments
After hysterectomy	No screening		Applies to women without a cervix and without a history of CIN2 or a more severe diagnosis in the past 20 y or cervical cancer ever
HPV vaccinated	Follow age-specific recommendations (same as unvaccinated women)		

ASCCP

The society for lower genital tract disorders since 1964.

Algorithms

Updated Consensus Guidelines for
Managing Abnormal Cervical Cancer
Screening Tests and Cancer Precursors

American Society for Colposcopy and Cervical Pathology

Reprinted – April 2013

Introduction

Cytology

Since the publication of the 2006 consensus guidelines, new cervical cancer screening guidelines have been published and new information has become available which includes key cervical cancer screening and follow up, and cervical precancer management data over a nine year period among more than 1 million women cared for at Kaiser Permanente Northern California. Moreover, women under age 21 are no longer receiving cervical cancer screening and cotesting with high-risk HPV type assays, and cervical cytology is being used to screen women 30 years of age and older.

Therefore, in 2012 the American Society for Colposcopy and Cervical Pathology (ASCCP), together with its 24 partner professional societies, Federal agencies, and international organizations, began the process of revising the 2006 management guidelines. This culminated in the consensus

conference held at the National Institutes of Health in September 2012. This report provides updated recommendations for managing women with cytological abnormalities. A more comprehensive discussion of these recommendations and their supporting evidence was published in the *Journal of Lower Genital Tract Disease and Obstetrics and Gynecology* and is made available on the ASCCP website at www.asccp.org.

Histopathology

Appropriate management of women with histo-pathologically diagnosed cervical precancer is an important component of cervical cancer prevention programs. Although the precise number of women diagnosed with cervical precancer each year in the U.S. is not known, it appears to be a relatively common occurrence. In 2001 and 2006, the American Society for Colposcopy and Cervical Pathology and 28 partner professional societies, federal agencies, and international organizations, convened processes to develop and update consensus guidelines for the management of women with

cervical precancer. Since then, considerable new information has emerged about management of young women, and the impact of treatment for precursor disease on pregnancy outcomes. Progress has also been made in our understanding of the management of women with adenocarcinoma in-situ, also a human papillomavirus (HPV)—associated precursor lesion to invasive cervical adenocarcinoma. Therefore, in 2012 the ASCCP, together with its partner organizations, reconvened the consensus process of revising the guidelines. This culminated in the September 2012 Consensus Conference held at the National Institutes of Health. This report provides the recommendations developed for managing women with cervical precancer. A summary of the guidelines themselves—including the recommendations for managing women with cervical cytological abnormalities — are published in *JLGTD and Obstetrics & Gynecology*.

General Comments

Although the guidelines are based on evidence whenever possible, for certain clinical situations limited high-quality evidence exists. In these situations the guidelines are based on consensus expert opinion. Guidelines should never be a substitute for clinical judgment. Clinical judgment should always be used when applying a guideline to an individual patient since guidelines may not apply to all patient-related situations. Finally, both clinicians and patients need to recognize that while most cases of cervical cancer can be prevented through a program of screening and management of cervical precancer, no screening or treatment modality is 100% effective and invasive cervical cancer can develop in women participating in such programs.

The 2001 Bethesda System terminology is used for cytological classification. This terminology utilizes the terms low-grade squamous intraepithelial lesion (LSIL) and high-grade squamous intraepithelial lesion (HSIL) to refer to low-grade lesions and high-grade cervical cancer precursors respectively. For managing cervical precancer, the histopathological classification is two-tiered applying the terms cervical intraepithelial neoplasia grade 1 (CIN 1) to low-grade lesions and CIN2,3 to high-grade lesions. If using the 2012 Lower Anogenital Squamous Terminology (LAST), CIN1 is equivalent to histopathological LSIL and CIN2,3 is equivalent to histopathological HSIL. Please note that cytological LSIL is not equivalent to histopathological CIN 1 and cytological HSIL

is not equivalent to histopathological CIN2,3. The current guidelines expand clinical indications for HPV testing based on studies using FDA-approved, validated HPV assays. Management decisions based on results using HPV tests not similarly validated may not result in outcomes intended by these guidelines. HPV testing should be restricted to high-risk (oncogenic) HPV types. Testing for low-risk (non-oncogenic) HPV types has no role in evaluating women with abnormal cervical cytological results. Therefore, whenever "HPV testing" is mentioned in the guidelines, it refers to testing for high-risk (oncogenic) HPV types only.

Definitions

Terms Utilized in the Consensus Guidelines

- **Colposcopy** is the examination of the cervix, vagina, and, in some instances the vulva, with the colposcope after the application of a 3-5% acetic acid solution coupled with obtaining colposcopically-directed biopsies of all lesions suspected of representing neoplasia.
- **Endocervical sampling** includes obtaining a specimen for either histopathological evaluation using an endocervical curette or a cytobrush or for cytological evaluation using a cytobrush.
- **Endocervical assessment** is the process of evaluating the endocervical canal for the presence of neoplasia using either a colposcope or endocervical sampling.
- **Diagnostic excisional procedure** is the process of obtaining a specimen from the transformation zone and endocervical canal for histopathological evaluation and includes laser conization, cold-knife conization, loop electrosurgical excision procedure (LEEP), and loop electrosurgical conization.
- **Adequate colposcopy** indicates that the entire squamocolumnar junction and the margin of any visible lesion can be visualized with the colposcope.
- **Endometrial sampling** includes obtaining a specimen for histopathological evaluation using an endometrial aspiration or biopsy device, a "dilatation and curettage" or hysteroscopy.

© Copyright, 2002, 2006, 2013 American Society for Colposcopy and Cervical Pathology. All rights reserved

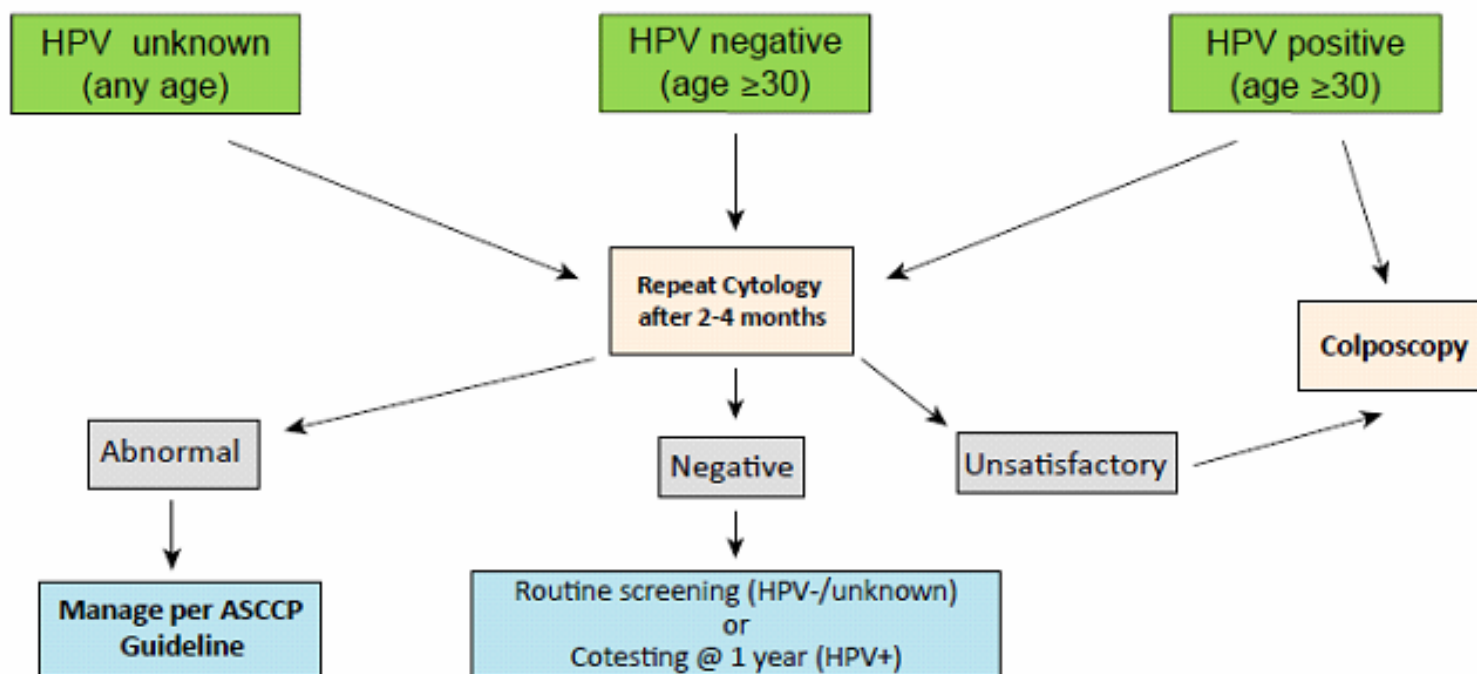
Acknowledgments

These guidelines were developed with funding from the American Society for Colposcopy and Cervical Pathology (ASCCP). The contents are solely the responsibility of the authors and the ASCCP.

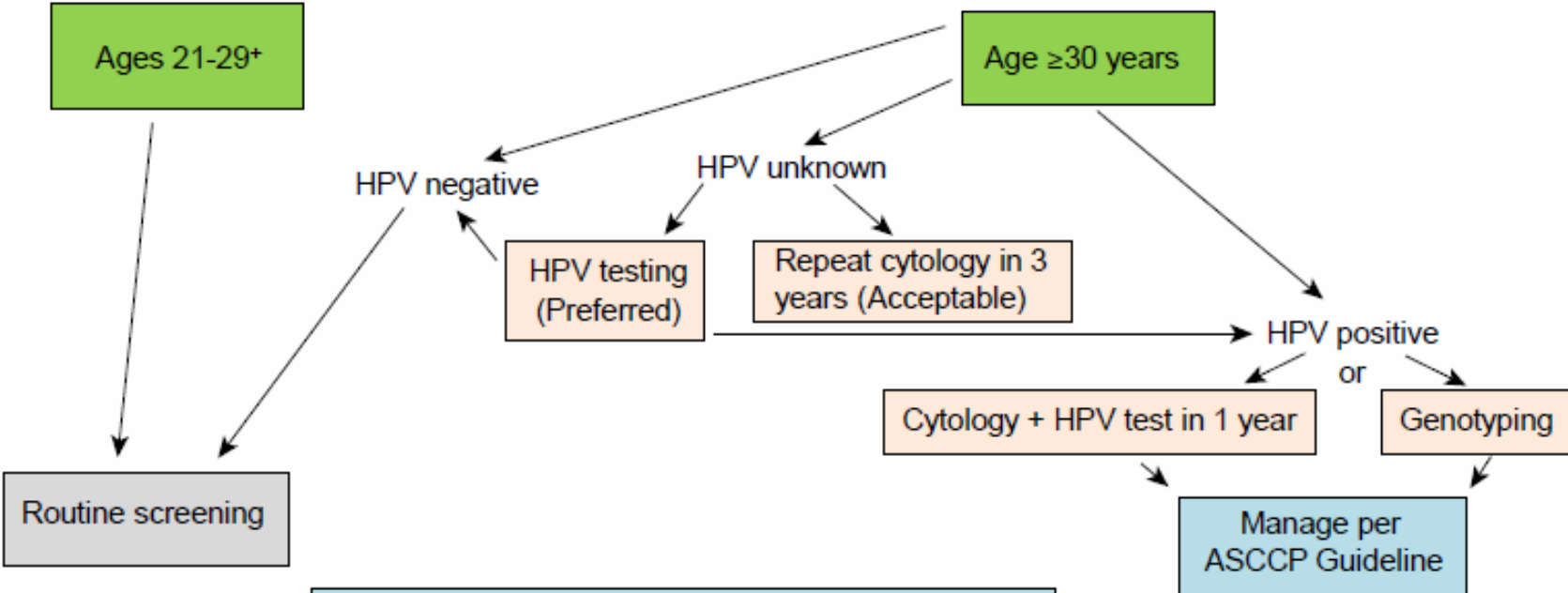
L. Stewart Massad, M.D., Washington University School of Medicine, St. Louis, MO; Mark H. Einstein, M.D., Albert Einstein College of Medicine, Bronx, NY; Warner K. Huh, M.D., University of Alabama School of Medicine, Birmingham, AL; Hormuzd A. Katki, Ph.D., Division of Cancer Epidemiology and Genetics, National Cancer Institute, Bethesda, MD; Walter K. Kinney, M.D., The Permanente Medical Group, Sacramento, CA; Mark Schiffman, M.D., Diane Solomon, M.D., Division of Cancer Prevention, National Cancer Institute, Bethesda, MD; Nicolas Wentzensen, M.D., Division of Cancer Epidemiology and Genetics, National Cancer Institute, Bethesda, MD; Herschel W. Lawson, M.D., Emory University School of Medicine, Atlanta, GA, on behalf of the 2012 ASCCP Consensus Guidelines Conference

All copyright permission requests should be sent to the ASCCP National Office, 1530 Tilco Dr., Ste. C, Frederick, MD 21704

Unsatisfactory Cytology

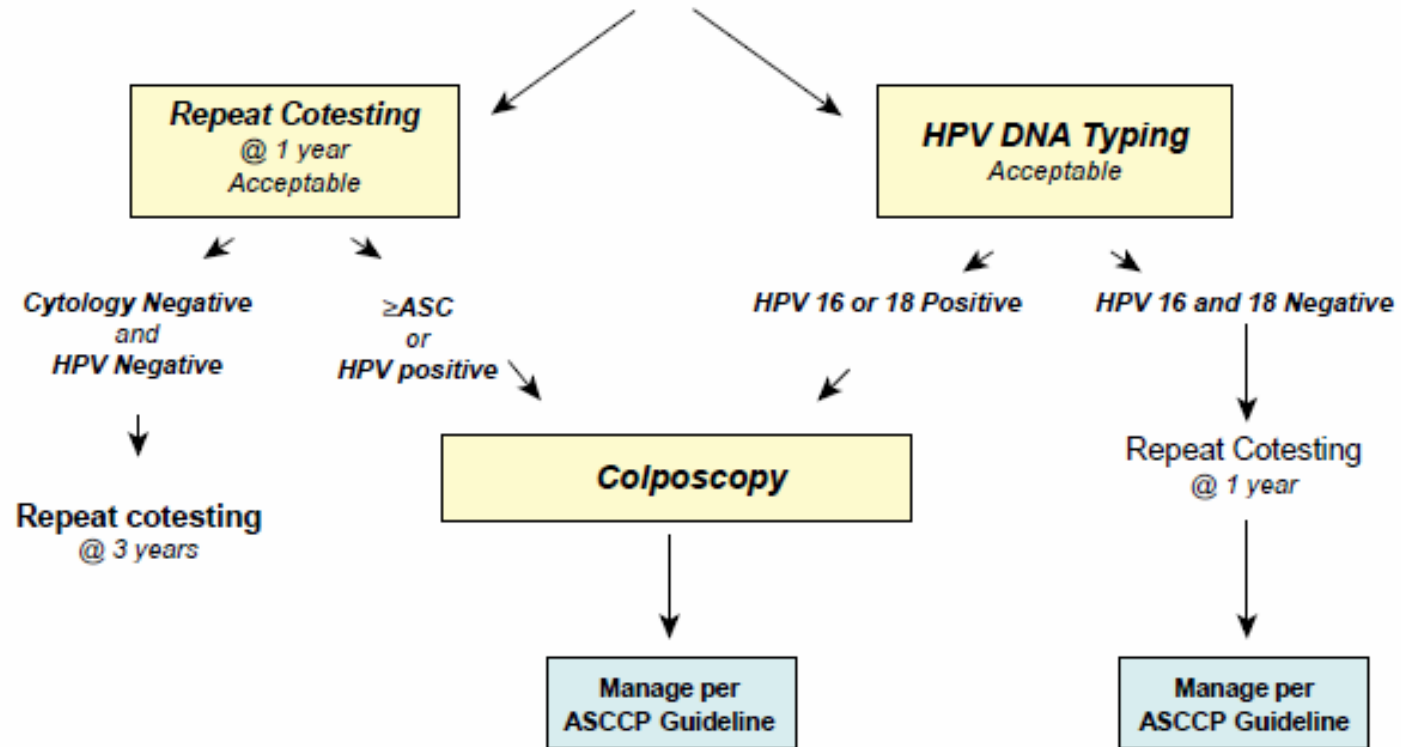


Cytology NILM* but EC/TZ Absent/Insufficient

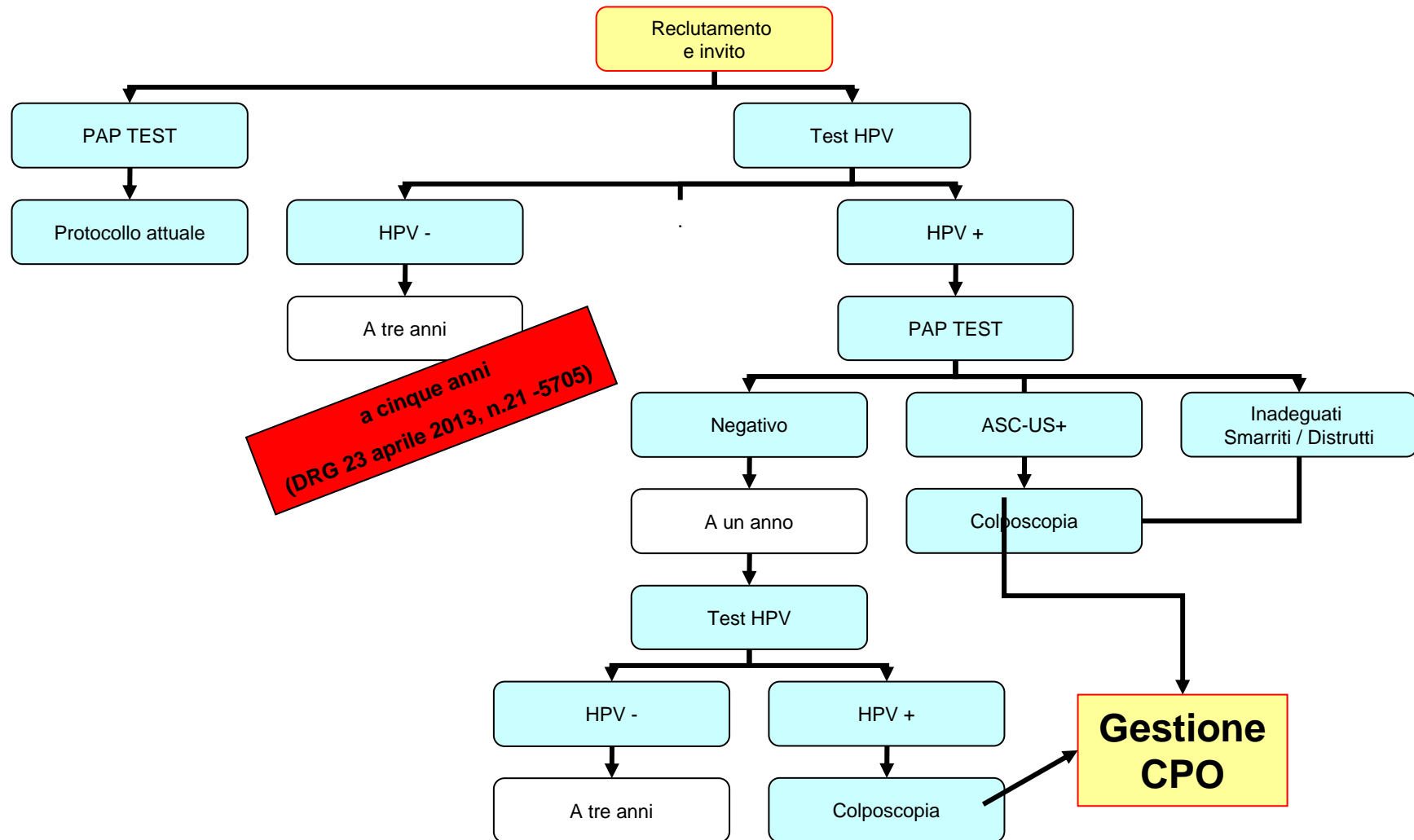


*Negative for intraepithelial lesion or malignancy
 *HPV testing is unacceptable for screening women ages 21-29 years

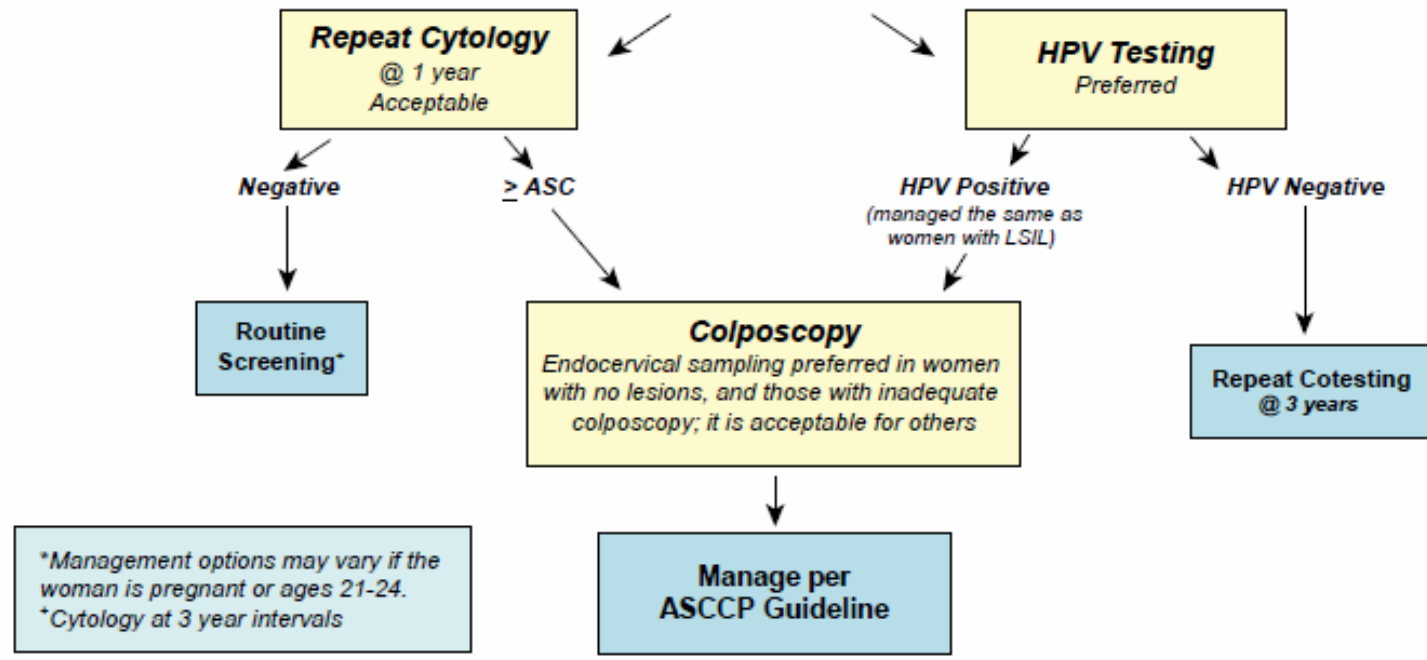
Management of Women \geq Age 30, who are Cytology Negative, but HPV Positive



PROTOCOLLO PROGETTO PILOTA

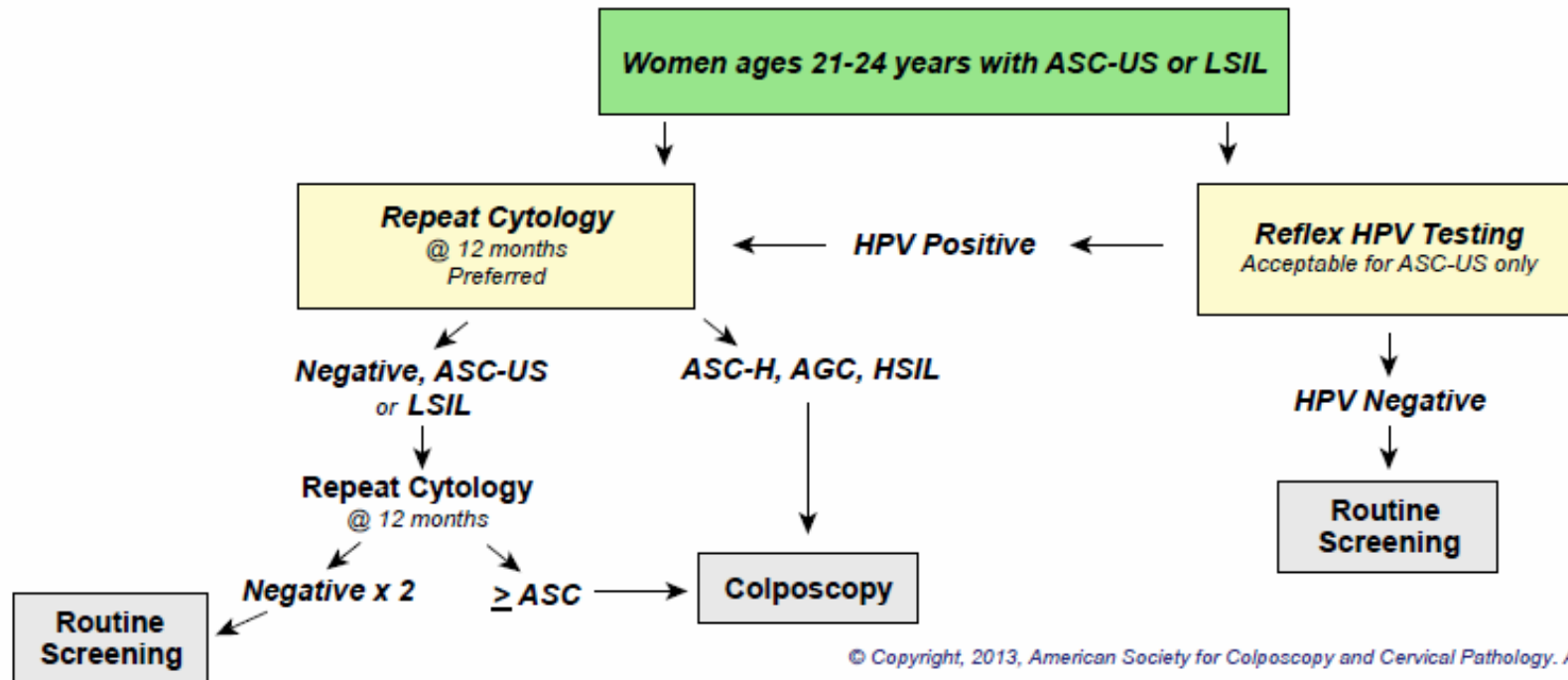


Management of Women with Atypical Squamous Cells of Undetermined Significance (ASC-US) on Cytology*

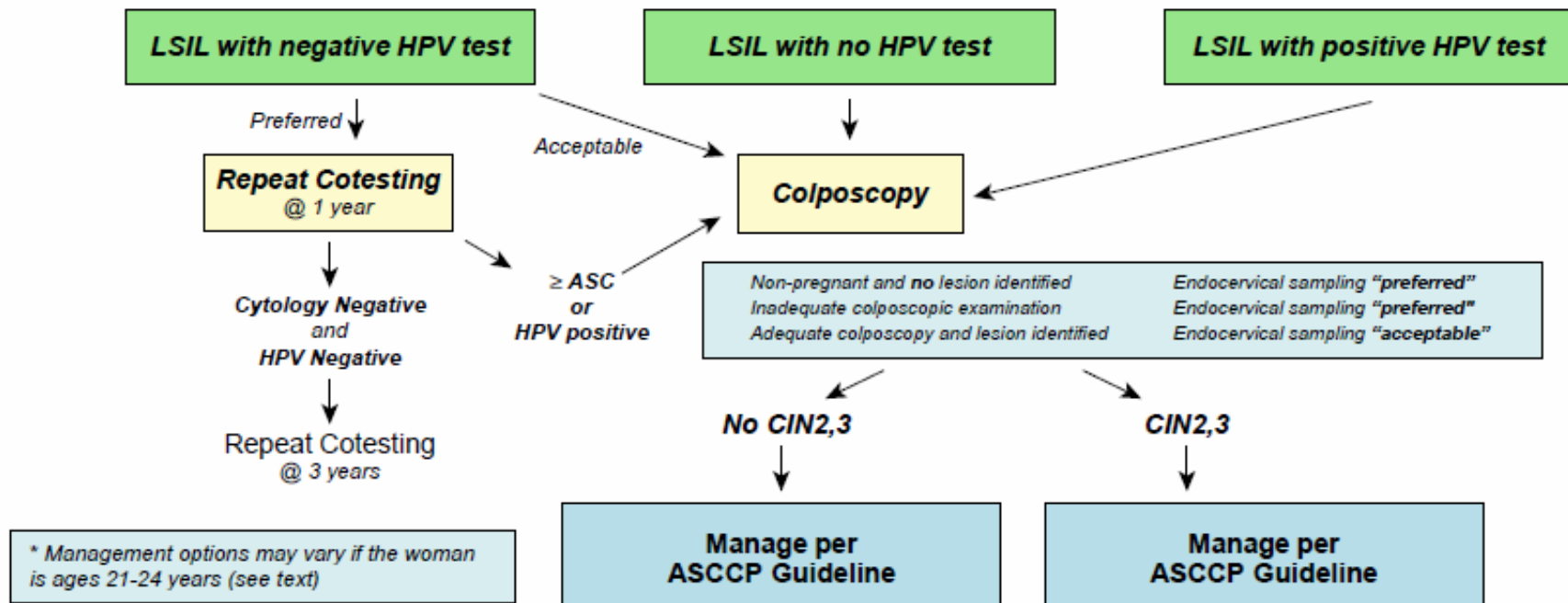


*Management options may vary if the woman is pregnant or ages 21-24.
*Cytology at 3 year intervals

Management of Women Ages 21-24 years with either Atypical Squamous Cells of Undetermined Significance (ASC-US) or Low-grade Squamous Intraepithelial Lesion (LSIL)

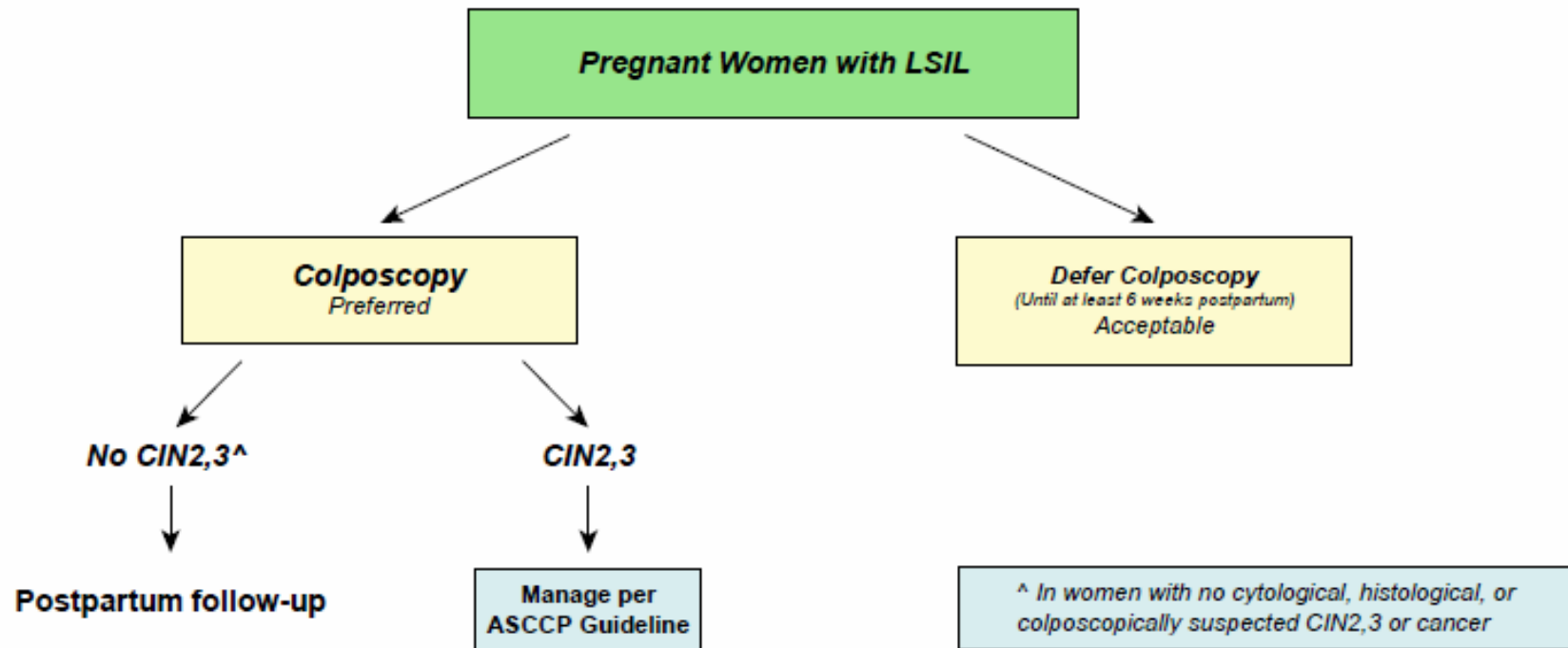


Management of Women with Low-grade Squamous Intraepithelial Lesions (LSIL)*

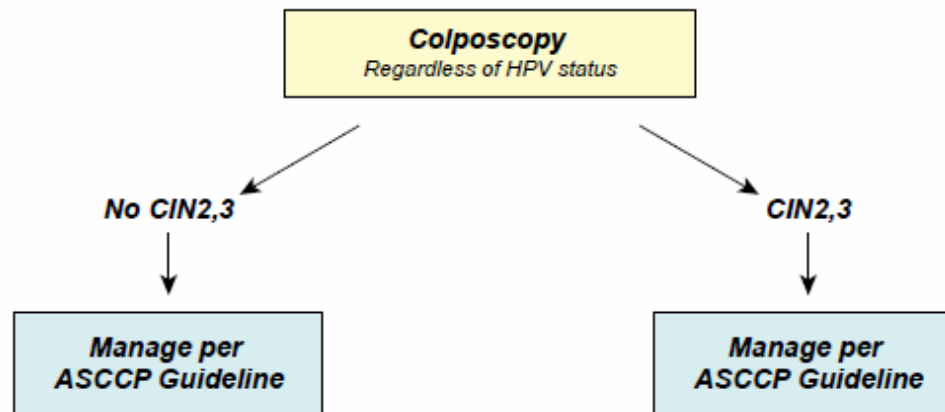


* Management options may vary if the woman is ages 21-24 years (see text)

Management of Pregnant Women with Low-grade Squamous Intraepithelial Lesion (LSIL)

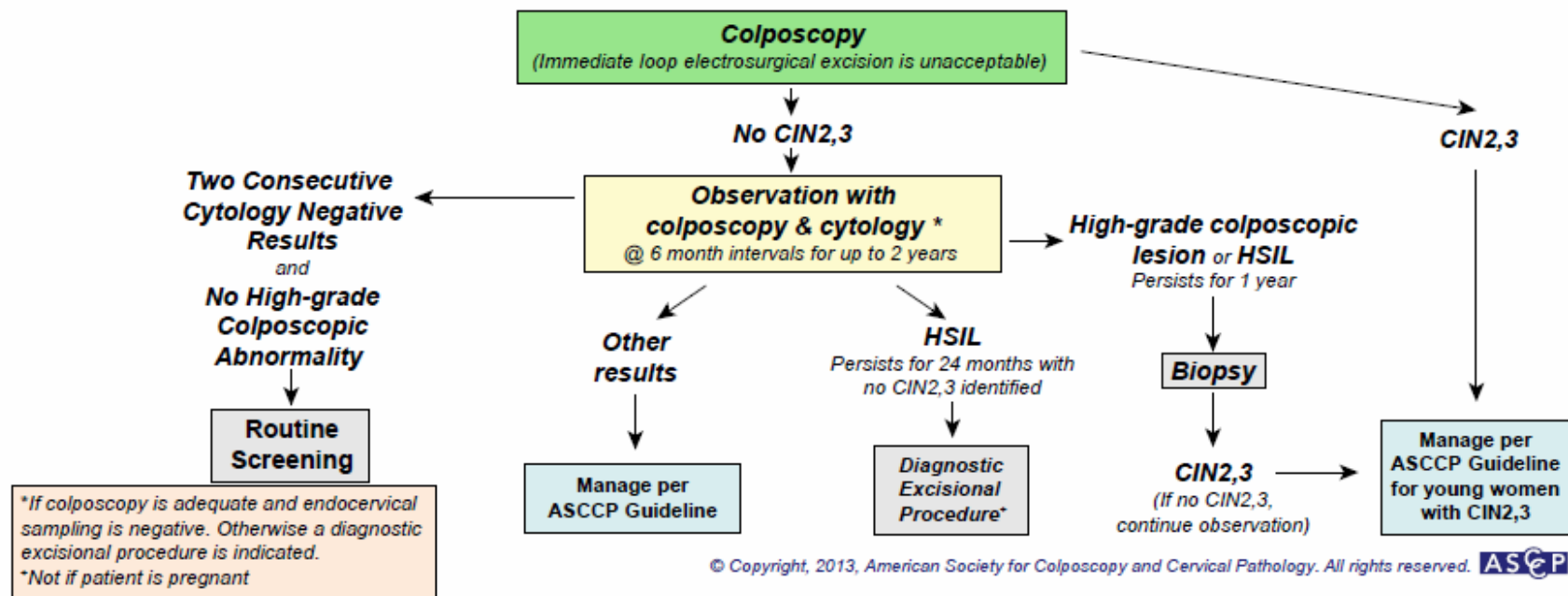


**Management of Women with Atypical Squamous Cells:
Cannot Exclude High-grade SIL (ASC-H)***

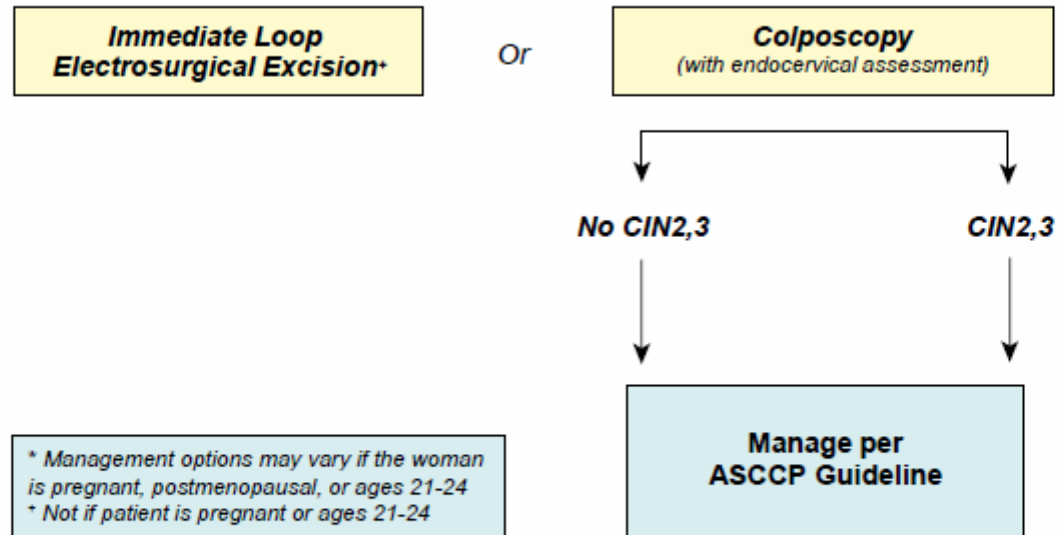


* Management options may vary if the woman is ages 21-24.

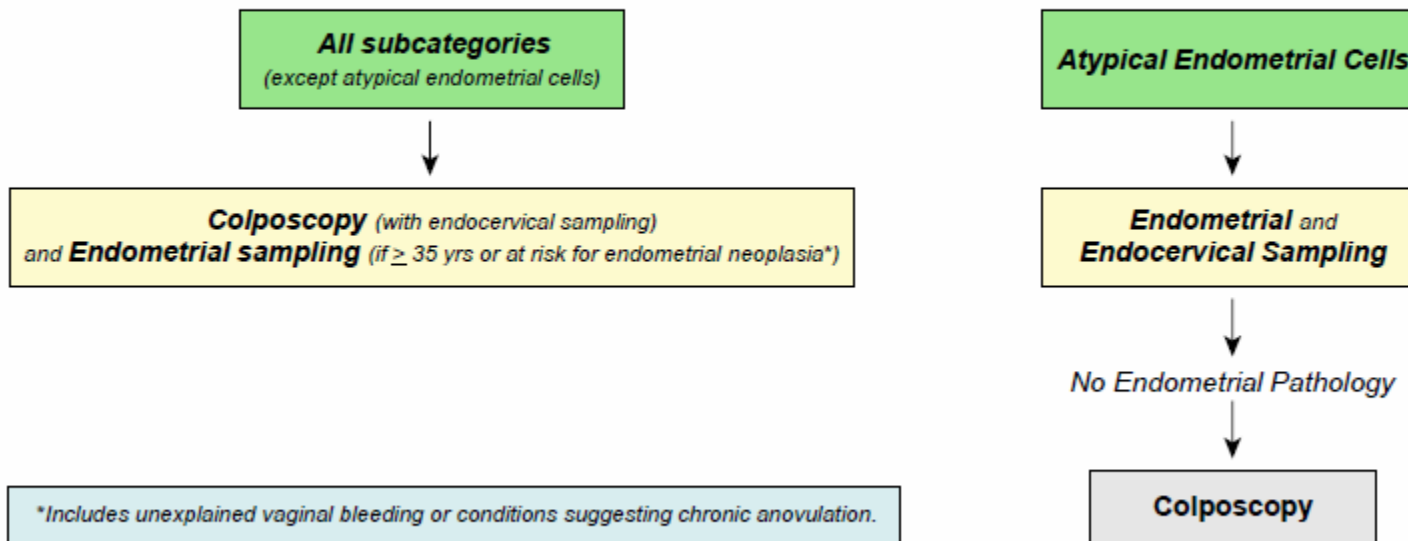
Management of Women Ages 21-24 yrs with Atypical Squamous Cells, Cannot Rule Out High Grade SIL (ASC-H) and High-grade Squamous Intraepithelial Lesion (HSIL)



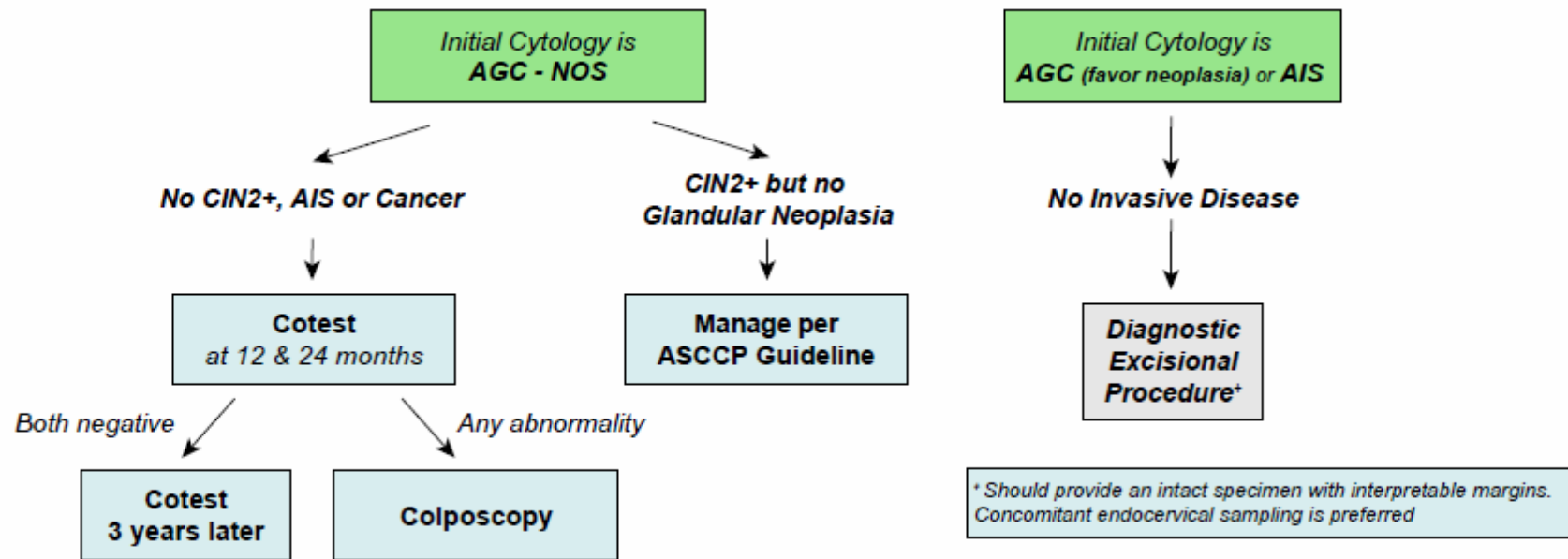
Management of Women with High-grade Squamous Intraepithelial Lesions (HSIL)*



Initial Workup of Women with Atypical Glandular Cells (AGC)

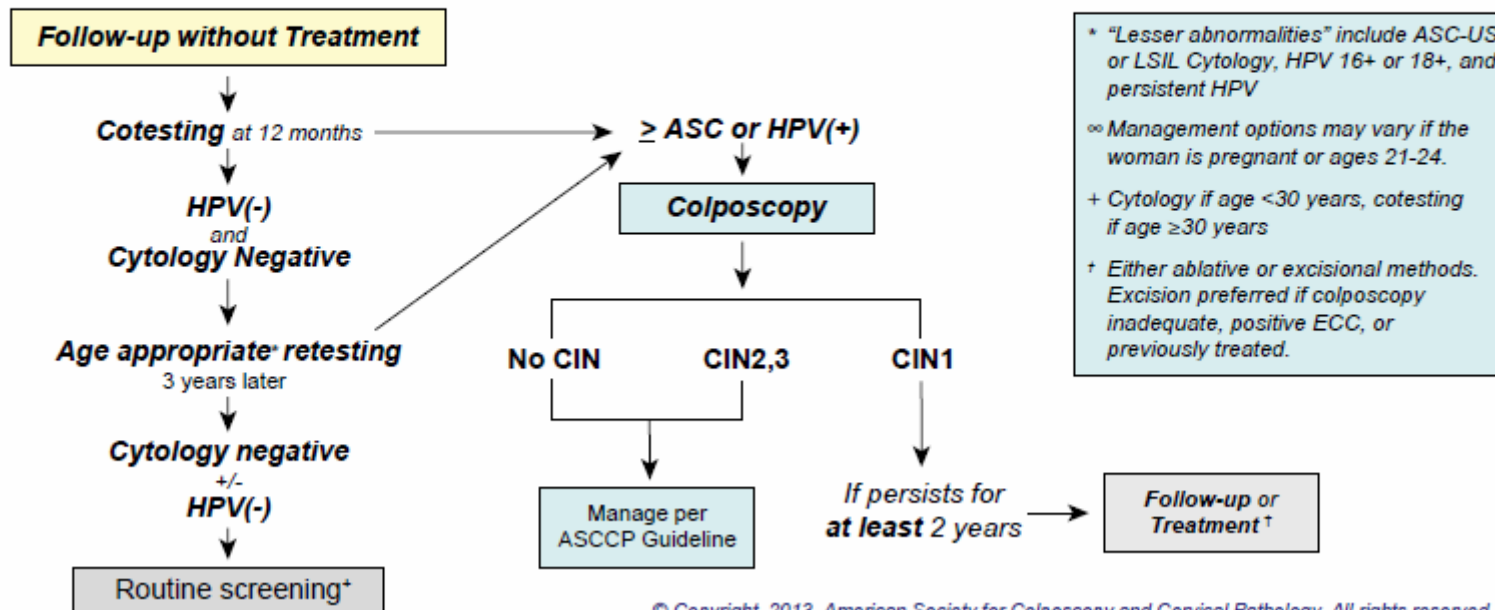


Subsequent Management of Women with Atypical Glandular Cells (AGC)

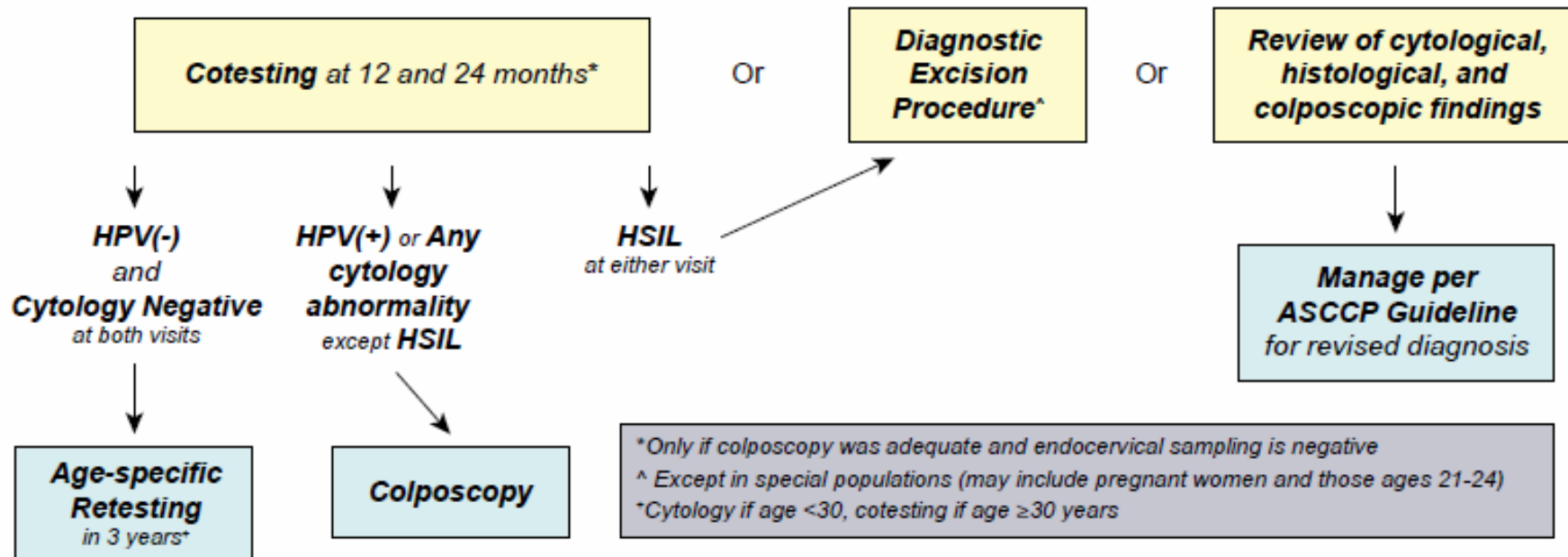


© Copyright, 2013, American Society for Colposcopy and Cervical Pathology. All rights reserved. **ASCP**

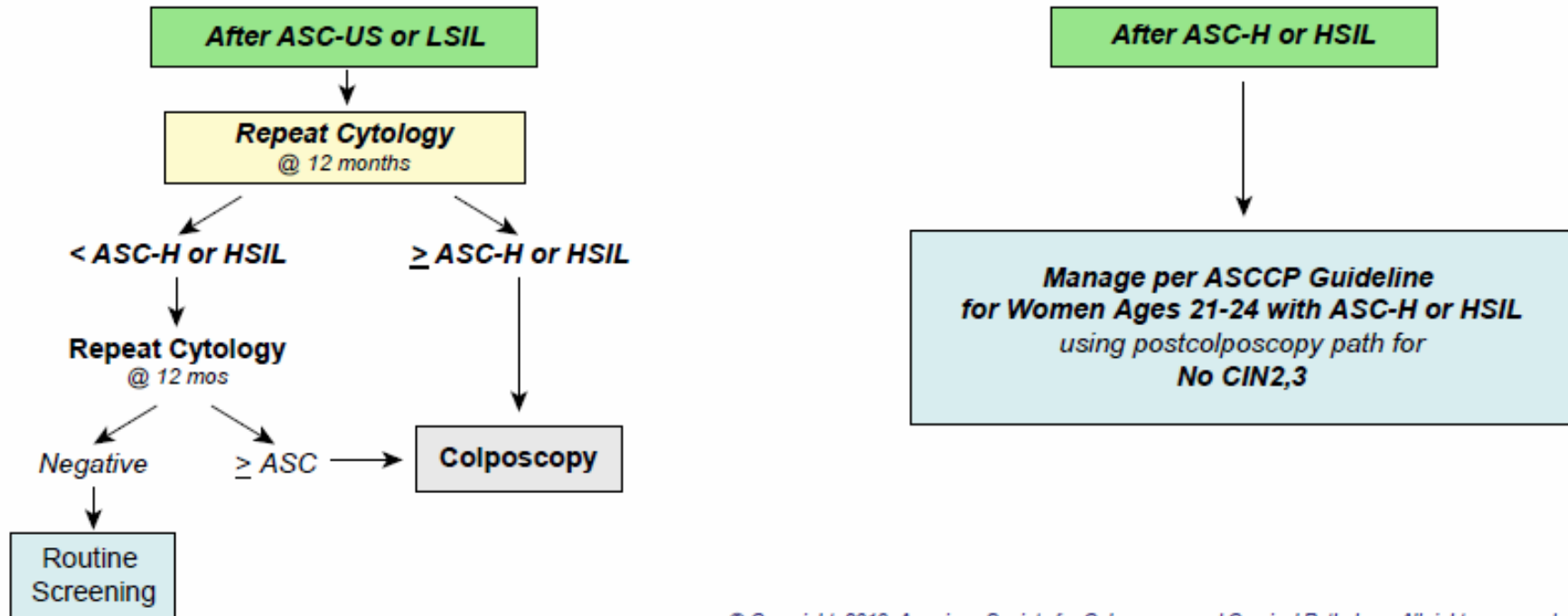
Management of Women with No Lesion or Biopsy-confirmed Cervical Intraepithelial Neoplasia — Grade 1 (CIN1) Preceded by “Lesser Abnormalities”^{*,∞}



Management of Women with No Lesion or Biopsy-confirmed Cervical Intraepithelial Neoplasia — Grade 1 (CIN1) Preceded by ASC-H or HSIL Cytology



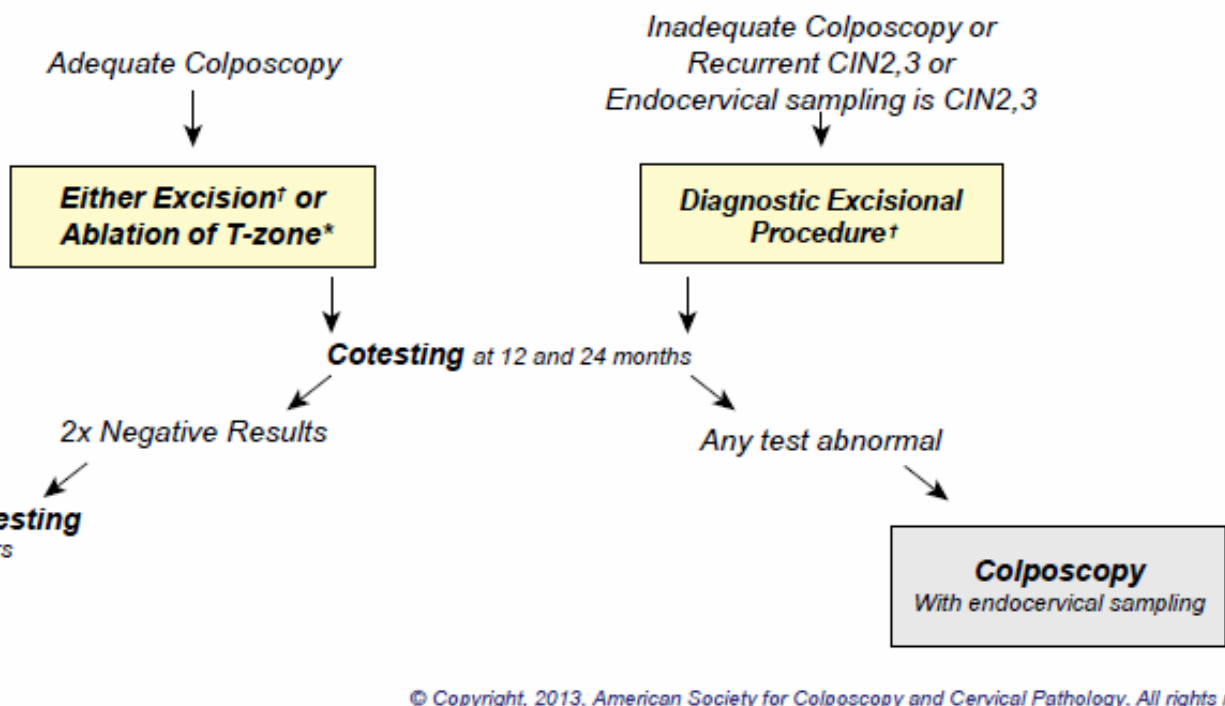
Management of Women Ages 21-24 with No Lesion or Biopsy-confirmed Cervical Intraepithelial Neoplasia — Grade 1 (CIN1)



Management of Women with Biopsy-confirmed Cervical Intraepithelial Neoplasia — Grade 2 and 3 (CIN2,3)*

*Management options will vary in special circumstances or if the woman is pregnant or ages 21-24

†If CIN2,3 is identified at the margins of an excisional procedure or post-procedure ECC, cytology and ECC at 4-6mo is preferred, but repeat excision is acceptable and hysterectomy is acceptable if re-excision is not feasible.

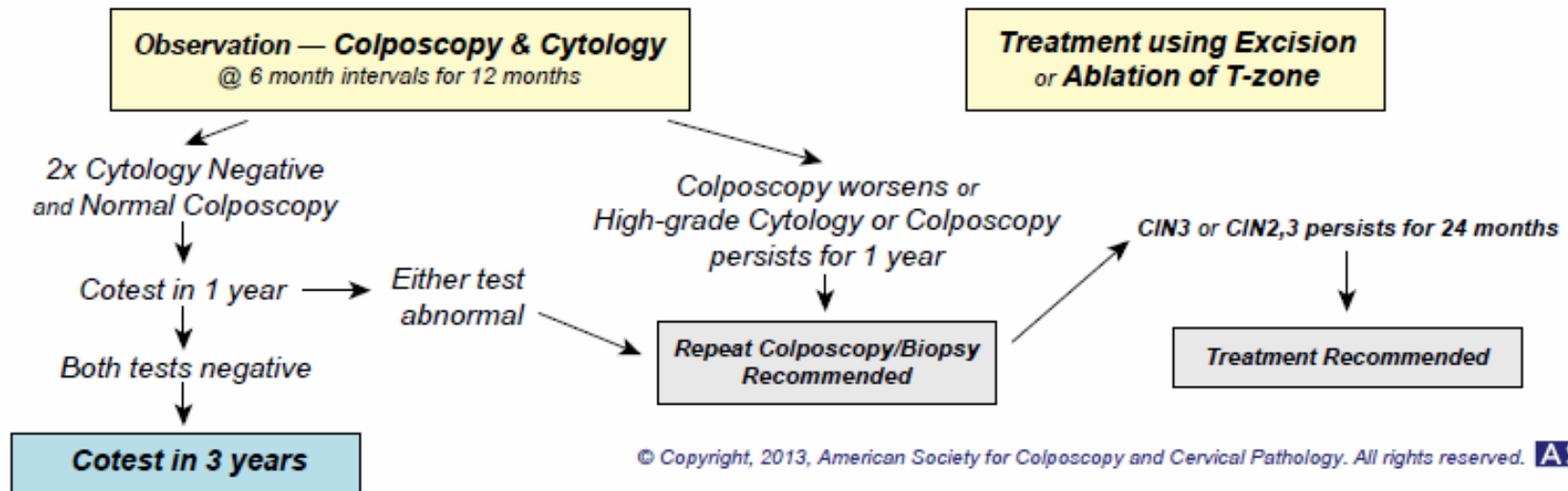


© Copyright, 2013, American Society for Colposcopy and Cervical Pathology. All rights reserved. **ASCP**

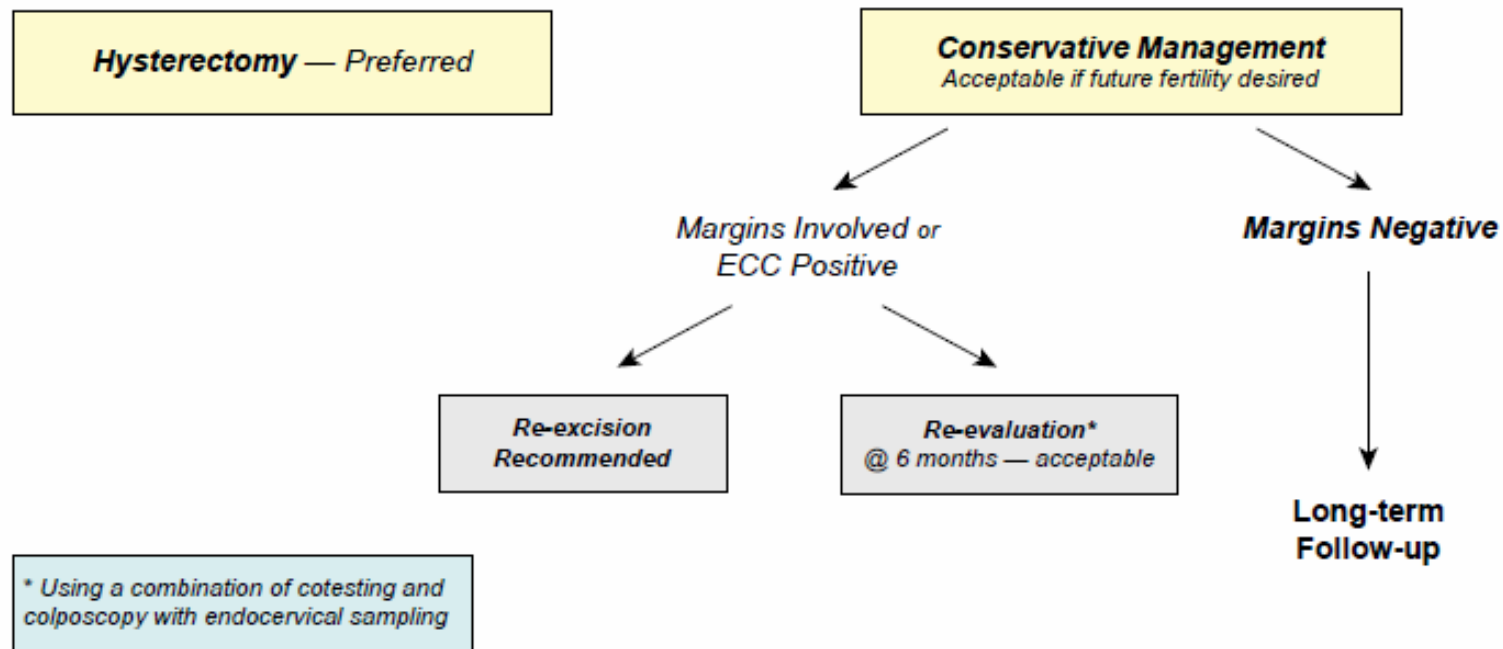
**Management of Young Women with Biopsy-confirmed Cervical Intraepithelial Neoplasia
— Grade 2,3 (CIN2,3) in Special Circumstances**

Young Women with CIN2,3

Either treatment or observation is acceptable, provided colposcopy is adequate. When CIN2 is specified, observation is preferred. When CIN3 is specified, or colposcopy is inadequate, treatment is preferred.

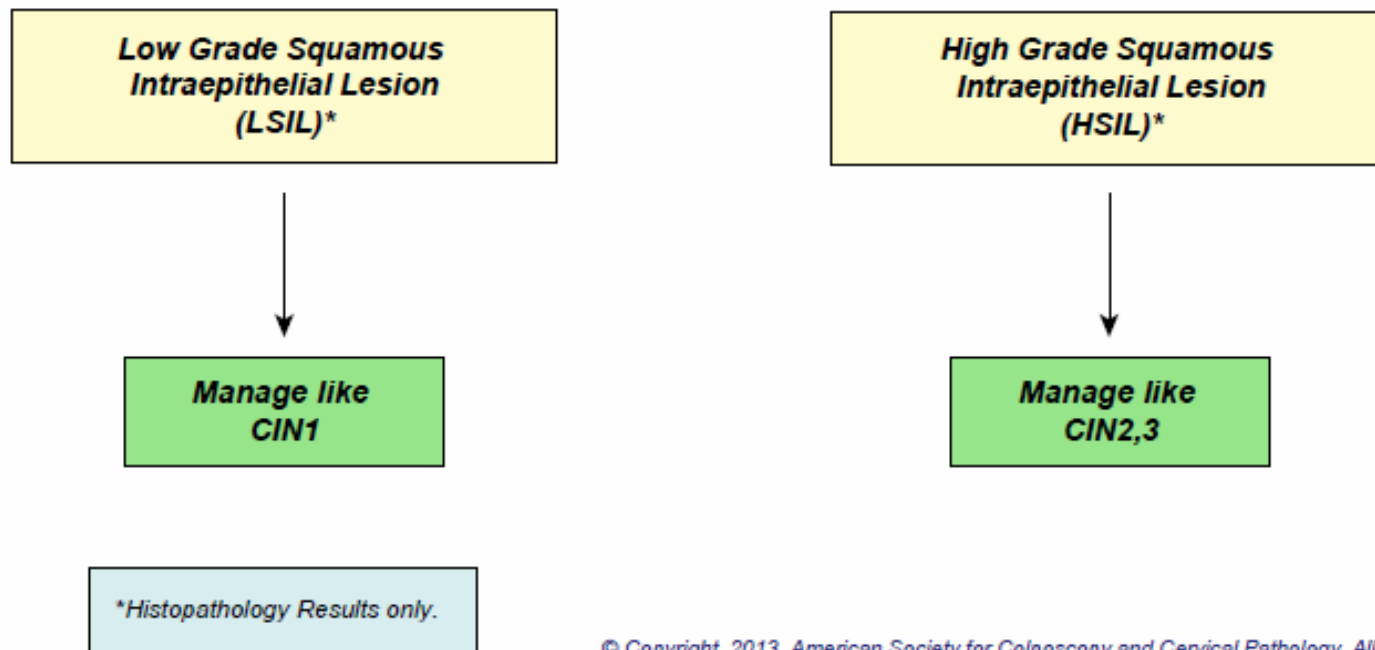


Management of Women Diagnosed with Adenocarcinoma in-situ (AIS) during a Diagnostic Excisional Procedure



© Copyright, 2013, American Society for Colposcopy and Cervical Pathology. All rights reserved. **ASCP**

Interim Guidance for Managing Reports using the Lower Anogenital Squamous Terminology (LAST) Histopathology Diagnoses



2012 Updated Consensus Guidelines for the Management of Abnormal Cervical Cancer Screening Tests and Cancer Precursors

L. Stewart Massad, MD, Mark H. Einstein, MD, Warner K. Huh, MD,
Hormuzd A. Katki, PhD, Walter K. Kinney, MD, Mark Schiffman, MD,
Diane Solomon, MD, Nicolas Wentzensen, MD, and Herschel W. Lawson, MD,
for the 2012 ASCCP Consensus Guidelines Conference

*From Washington University School of Medicine, St. Louis, Missouri; Albert Einstein College of
Medicine, New York, New York; University of Alabama School of Medicine, Birmingham,
Alabama; Division of Cancer Epidemiology and Genetics and Division of Cancer Prevention,
National Cancer Institute, Bethesda, Maryland; The Permanente Medical Group, Sacramento,
California; and Emory University School of Medicine, Atlanta, Georgia*

Box 1. Essential Changes From Prior Management Guidelines*

- Cytology reported as negative but lacking endocervical cells can be managed without early repeat.
- CIN 1 on endocervical curettage should be managed as CIN 1, not as a positive ECC.
- Cytology reported as unsatisfactory requires repeat even if HPV negative.
- Genotyping triages HPV-positive women with HPV type 16 or type 18 to earlier colposcopy only after negative cytology; colposcopy is indicated for all women with HPV and ASC-US, regardless of genotyping result.
- For ASC-US cytology, immediate colposcopy is not an option. The serial cytology option for ASC-US incorporates cytology at 12 months, not 6 months and 12 months, and then if negative, cytology every 3 years.
- HPV-negative and ASC-US results should be followed with co-testing at 3 years rather than 5 years.
- HPV-negative and ASC-US results are insufficient to allow exit from screening at age 65 years.

Box 1. Essential Changes From Prior Management Guidelines*

- The pathway to long-term follow-up of treated and untreated CIN 2+ is more clearly defined by incorporating co-testing.
- More strategies incorporate co-testing to reduce follow-up visits. Pap-only strategies are now limited to women younger than 30 years, but co-testing is expanded even to women younger than 30 years in some circumstances. Women aged 21-24 years are managed conservatively.

CIN, cervical intraepithelial neoplasia; ECC, endocervical curettage; HPV, human papillomavirus; ASC-US, atypical squamous cells of undetermined significance.

**Prior management guidelines were from the "2006 Consensus Guidelines for the Management of Women With Abnormal Cervical Screening Tests" (6). Prior guidelines not changed were retained.*

2012 Updated Consensus
Guidelines for the Management of
Abnormal Cervical Cancer
Screening Tests and Cancer
Precursors

Box 2.

A recent consensus conference (the Lower Anogenital Squamous Terminology [LAST] Project convened by the College of American Pathologists and the American Society for Colposcopy and Cervical Pathology) adopted a two-tier terminology that incorporates ancillary tests and other criteria to distinguish indeterminate lesions as high grade or low grade. Until a comprehensive evidence review and consensus guidelines development process can be conducted, histopathology results reported as low-grade squamous intraepithelial lesions (LSIL) should be managed as cervical intraepithelial neoplasia (CIN) 1 and those reported as high-grade squamous intraepithelial lesions (HSIL) should be managed as CIN 2,3 (14).

Grazie
per l'attenzione